



*Dynamic Chiropractic* – September 1, 1996, Vol. 14, Issue 18

## **The Increasingly Common Trochanteric Bursitis**

By John Palo

Editor's note: A graduate of National College of Chiropractic, Dr. Palo is a professor emeritus at New York Chiropractic College for the DABCO program, and served as assistant director of the New York City Department of Health's chiropractic division.

---

Are you seeing more patients with trochanteric bursitis? This office is. Their history reveals most of them use a shoulder strap carrying bag. We've come to the following conclusion. The bag is hitting upon and irritating at the femur's greater trochanter. Back and forth, as they walk, the bag rubs on the femoral prominence. This continuous irritation soon initiates as inflammation of the bursa overlying the greater trochanter, i.e., trochanteric bursitis.

image

### **Diagnosis**

That patient presents with an exquisite pain over the involved greater trochanter. It hurts if he sleeps on the involved side. Digital pressure at the greater trochanters elicits much greater pain at the involved side.

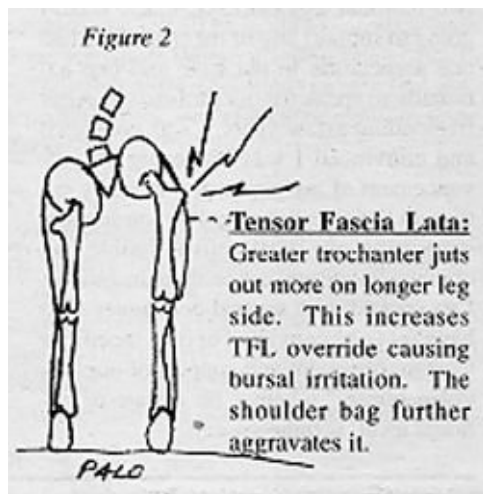
In diagnosing trochanteric bursitis we should check for hip osteoarthritis. OA can also present pain in the hip area, especially just above the greater trochanter. A positive Patrick test<sup>1</sup> for OA should lead to an x-ray to confirm hip joint osteoarthritis. As in trochanteric bursitis, sleeping on the involved side, in OA, also emits hip area pain. However, the bursitis pain is usually directly on the greater trochanter. It is more pin-pointed, i.e., less dispersed than OA pain.

We may also bear in mind hip OA may also reflect in the groin. Of course, so may a sacroiliac subluxation. However, a trochanteric bursitis will be negative with the Yeoman sacroiliac test<sup>2</sup> and will not elicit groin pain.

## A Longer Leg

The long leg<sup>3</sup> side is more prone to trochanteric bursitis than the shorter leg side. At the shorter leg side the greater trochanter goes lateral and is more prominent. This jutting out of the greater trochanter makes it more vulnerable. Even with no bag rubbing at the long leg's greater trochanter protrusion, this office has found runners prone to longer leg side trochanteric bursitis. This "runner's bursitis" is from repetitive greater override of the tensor fascia lata over the greater trochanter.

Pointed pain at the greater trochanter and a negative Patrick test should provide a good "working" diagnosis of greater trochanteric bursitis. Of course, if a longer leg is present it should be attended to so as to reduce the patient's greater vulnerability on the longer leg side.



## Treatment

1. The immediate treatment for trochanteric bursitis is ice. This should reduce the bursa inflammation.
2. The patient should be advised to shift the carrying bag to the other side. This stops the cause.
3. In both hip OA and trochanteric bursitis, patient should refrain from sleeping on the involved side.

4. Should the doctor discover a long leg contributing factor the patient should be provided a compensatory heel lift for the short leg shoe.

(In viewing hundreds of people walking the streets, this author estimates about one in three are currently using a shoulder strap carrying bag. Unfortunately, the bag usually falls directly upon the greater trochanter. The heavier the bag, the greater the irritation. The greater the irritation, the greater the chance of trochanteric bursitis. As more and more use should strap bags, doctors of chiropractic should be alert to the increasing prevalence of trochanteric bursitis.)

### *References*

1. Palo, J. Basic Orthopedic and Neurological Tests for the Office. New York, 1994.
2. Ibid.
3. Ibid.

*John Palo, BS, DC, CCSP, DABCO*

*New York, New York*



Page printed from:

[http://www.chiroweb.com/mpacms/dc/article.php?id=39279&no\\_paginate=true&p\\_friendly=true&no\\_b=true](http://www.chiroweb.com/mpacms/dc/article.php?id=39279&no_paginate=true&p_friendly=true&no_b=true)