

[IMAGE]

*Dynamic Chiropractic* – July 2, 2001, Vol. 19, Issue 14

## **Carpal Tunnel Exercises that Work**

By Warren Hammer, MS, DC, DABCO

Recently, I have been using exercises for carpal tunnel problems that seem to be speeding healing. The exercises are based on the principle of improving the movement of peripheral nerves. If the nerves are unable to move, glide and stretch, then the nervous system's cardinal function of conduction will be useless.<sup>1</sup> This loss of nerve movement may even be responsible for the symptoms of simple forearm strain. MRI scans of patients with nonspecific arm pain from repetitive strain (without any neurological signs or symptoms of carpal tunnel) may show reduced median-nerve movement in the carpal tunnel.<sup>2</sup>

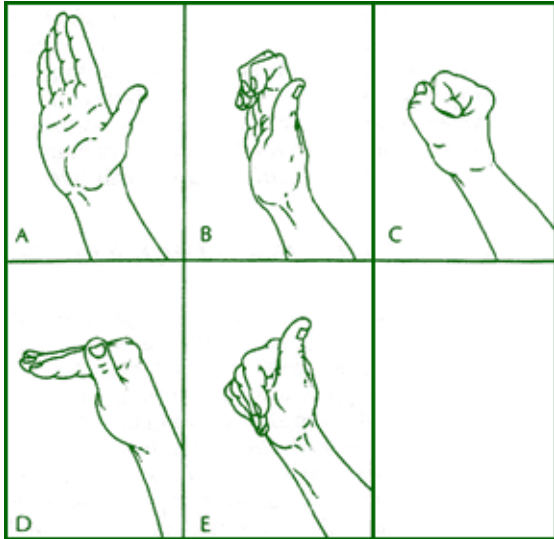
At the wrist, as in most areas of the body, nerves require a normal longitudinal movement. Flexion of the digits causes the median nerve to slide proximally into the forearm; with finger extension, the median nerve slides distally toward the hand.<sup>3</sup> Hyperextension of the wrist and fingers causes the median nerve to displace farthest under the transverse carpal ligament into the hand (10-15mm relative to a fixed bony landmark in the carpal tunnel). Displacement of the median nerve during flexion of wrist and fingers is two to four times greater at the wrist than in the upper arm.<sup>4</sup> It is important that the median nerve slides during movement instead of continually being stretched.

There should be a normal movement relationship in the carpal tunnel between the median nerve and the flexor tendons. It is thought that chronic repetitive use of the fingers may create a shearing between these structures, resulting in localized hyperplasia and fibrosis of the investing *tenosynovium* of the flexor tendons, and median nerve in the tunnel.<sup>4</sup> Adhesions between the median nerve and surrounding structures, especially the flexor tendons, results in stretching of the nerve. In the wrist, flexor tendon excursion is nearly five times greater than that of the median nerve.<sup>4</sup> They have found arteriolar and venular smooth-muscle hypertrophy and endothelial thickening increasing the pressure on the median nerve and its vascular supply.<sup>5</sup>

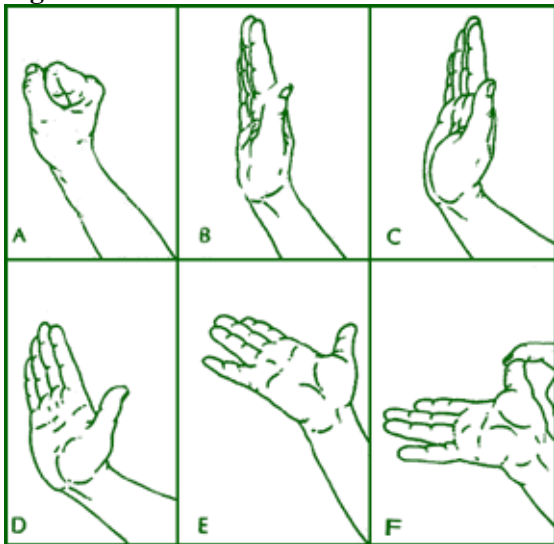
In a study using the following exercises, patients were instructed to place the affected hand in warm water for four minutes, and then cold water for one minute (three to five times a day). Each position (**see figures 1 and 2**) for mobilizing the median nerve was maintained for seven seconds, and repeated five times at each

session, for a total of three to five sessions per day.

**Figure 1:**



**Figure 2:**



Positions for extension tendon gliding exercises: (see **Figure 2**)

1. wrist is in neutral, with the fingers and thumb in flexion;
2. wrist is in neutral, with the fingers and thumb extended;
3. wrist and fingers are extended, with the thumb in neutral;
4. wrist, fingers, and thumb are extended;

5. wrist, fingers, and thumb are extended, with the forearm in supination; and
6. wrist, fingers and thumb are extended, the forearm is in supination, and the other hand gently stretches the thumb.

In this study,<sup>4</sup> one group of carpal tunnel patients was treated by standard methods, and another group included the nerve and tendon gliding exercises. Of the group that did not do the exercises, 71.2 percent underwent surgery, compared with only 43 percent of the patients who did the exercises.

### *References*

1. Butler DS. *The Sensitive Nervous System*. Adelaide, Australia, Noigroup Publications, 2000:98.
2. Greening J, Smart S, Leary R, et al. Reduced movement of median nerve in carpal tunnel during wrist flexion in patients with nonspecific arm pain. *Lancet*, 354, 1999:217-18.
3. Wilgis EFS, Murphy R. The significance of longitudinal excursion in peripheral nerves. *Hand Clinics*, 2, 1986:761-6.
4. Rozmaryn LM, Dovel S, Rothman ER, et al. Nerve and tendon gliding exercises and the conservative management of carpal tunnel syndrome. *J Hand Ther* 11, 1998:171-179.
5. Kerr CD, Sybert DR, Albarracin NS. An analysis of the *flexor synovium* in idiopathic carpal tunnel syndrome: report of 625 cases. *J Hand Surg.* 17A, 1992:1028-30.

*Warren Hammer, MS, DC, DABCO*

*Norwalk, Connecticut*

theham@discovernet.net

---

Click [here](#) for more information about Warren Hammer, MS, DC, DABCO.



Page printed from:

[http://www.chiroweb.com/mpacms/dc/article.php?id=18110&no\\_paginate=true&p\\_friendly=true&no\\_b=true](http://www.chiroweb.com/mpacms/dc/article.php?id=18110&no_paginate=true&p_friendly=true&no_b=true)